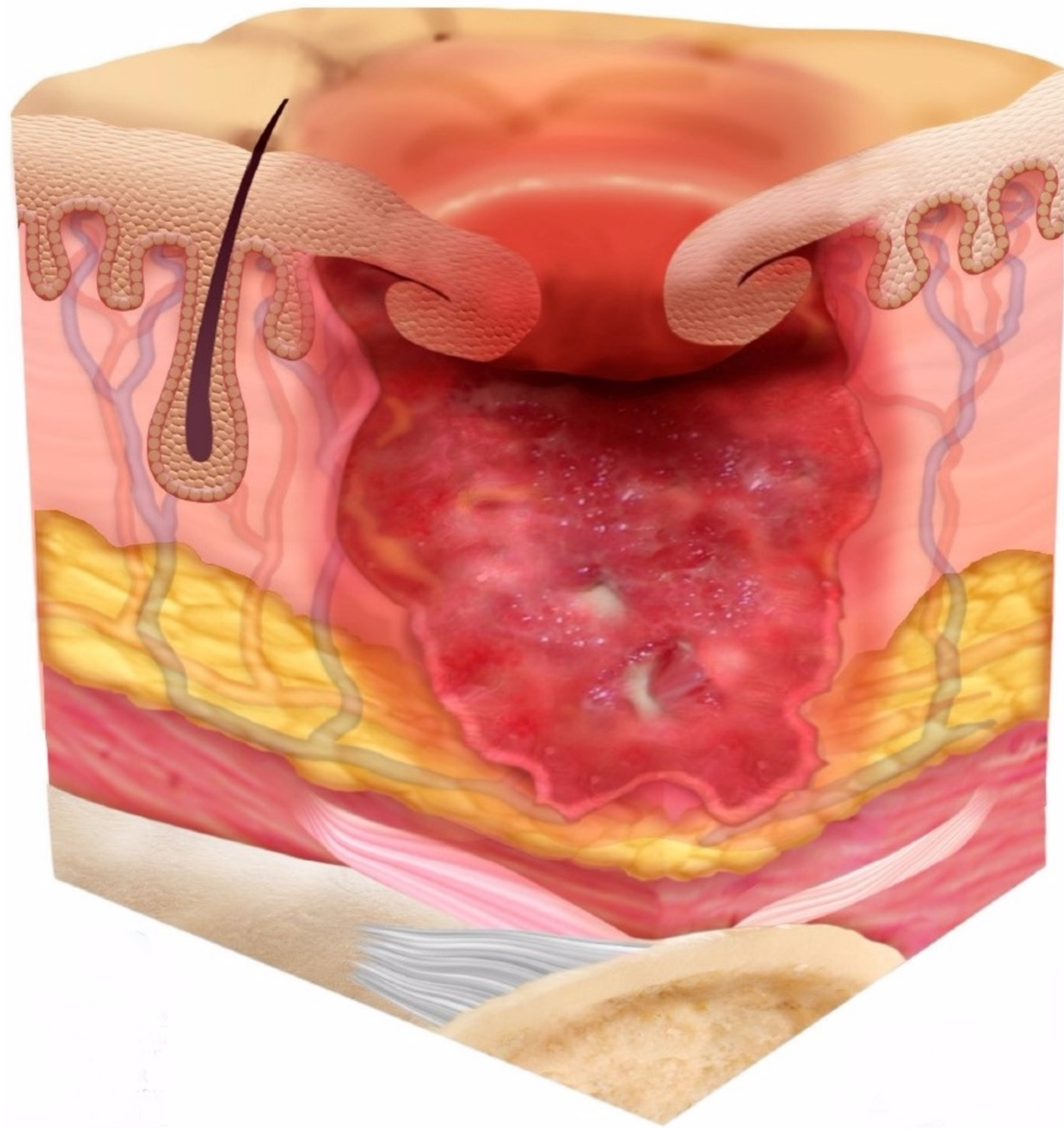


# Additional Examples

## Epibole

Wound edges that appear rolled under or curled

Edges may feel dry or callused



## Undermining

Tissue in a wound deteriorates causing a pocket underneath of the surrounding skin

## Tunneling

A narrow passage in the wound that extends into the fat and muscle of the wound

